

EDUCATIONAL MOMENTS®



VISION CARE INSTITUTE

How to manage patients with
Limbal Redness (Limbal Hyperaemia)

WHAT YOU NEED TO KNOW

Slit Lamp Viewing:

1. Diffuse beam
2. Medium magnification (16x)
3. Direct illumination

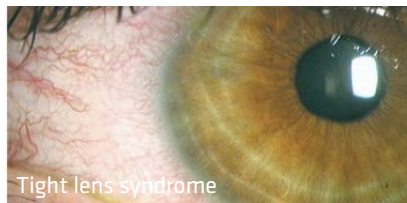
Grading:

Grade 0	Grade 1	Grade 2
		<p>Grade 0: None Grade 1: Slight injection of conjunctival vessels Grade 2: Mild injection Grade 3: Moderate injection Grade 4: Severe injection Position: Superior, nasal, inferior, temporal</p>

Incidence:

True incidence unknown although common in many lens types. Occurs to some degree with all hydrogel lenses

Aetiology:



- Short-term clinical sign of corneal hypoxia – related to oxygen performance of lens
- Inflammation (contact lens associated red eye, ie. CLARE or tight lens syndrome, left)
- Mechanical irritation (trauma, poor lens fit)
- Atopic/allergic reaction
- Solution toxicity
- Infection

Symptoms:

- Often none; depends on cause
- Possible pain

Signs:

- Engorged limbal blood vessels with possible subsequent neovascularisation
- May be localised or full coverage, depending on lens type or aetiology, with conjunctival vessel involvement

EDUCATIONAL MOMENTS[®]



How to manage patients with
Limbal Redness (Limbal Hyperaemia)

WHAT YOU NEED TO RECOMMEND TO YOUR PATIENTS

Recommendations :

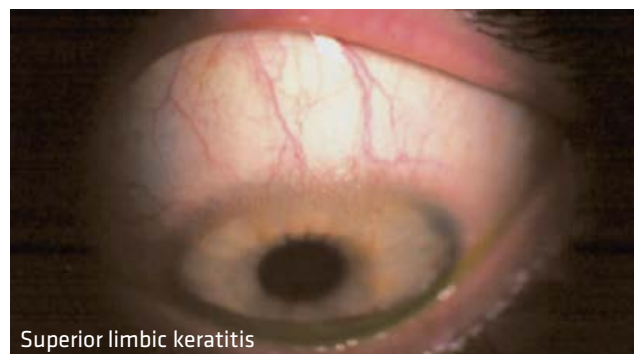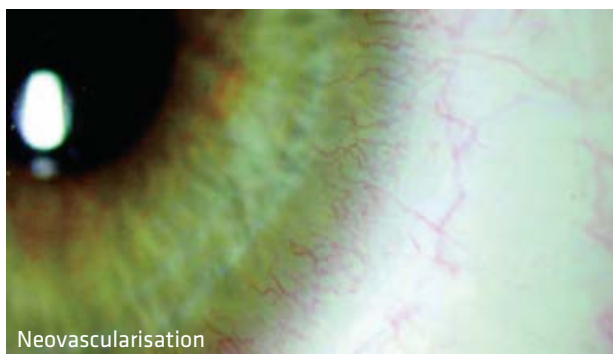
- Manage if \geq grade 2 or if \geq 1 grading scale interval increase or if symptoms occur
- Cease lens wear until resolution. Refit with high oxygen performance lens materials (SiH, RGP)
- Reduce wearing time or change to DW
- Optimise lens fit
- Remove allergen
- Change care system

Prognosis:

- Good – depends on cause
- Reversible
- Noticeable ‘white-eye’ difference between SiH and traditional hydrogels

Differential Diagnosis:

Neovascularisation, superior limbic keratitis, keratitis, contact lens associated red eye (CLARE or tight lens syndrome), uveitis , acute glaucoma, intraocular infection



HOW TO FIND OUT MORE

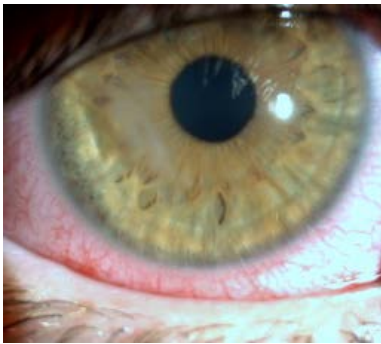- ❖ Click [here](#) for a general refresher on slit lamp techniques
- ❖ Click [here](#) to watch our educational video on slit lamp examination using diffuse illumination
- ❖ Click [here](#) for THE VISION CARE INSTITUTE[®] clinical grading scales and assessment guide

EDUCATIONAL MOMENTS®



How to manage patients with Limbal Redness (Limbal Hyperaemia)

PATIENT CASE STUDY



Patient JB is a 41-year-old shift worker who has worn monthly replacement hydrogel lenses for the past 20 years.

She attends for a routine aftercare appointment reporting no problems with the comfort of her lenses or with her vision.

She remarks that her eyes sometimes look red after working long, irregular hours, which she attributes to 'tiredness'.

Quiz:

1. What are the advantages of diffuse illumination and low magnification for examining the limbal conjunctiva?

- A. Even illumination
- B. Easy comparison of colours
- C. Large depth of field
- D. All of these

2. What grade would you give to her limbal hyperaemia?

- A. Grade 1
- B. Grade 2
- C. Grade 3
- D. Grade 4

3. What do the possible causes of this appearance include?

- A. Corneal hypoxia
- B. Poor lens fit
- C. Infection
- D. All of these

4. Which of the following management options would you be most likely to choose?

- A. Refit with two-weekly replacement silicone hydrogel (SiH) lenses
- B. Refit with RGP lenses
- C. Discontinue lens wear permanently
- D. Referral to the patient's GP

Correct answers:

- 1: D. All of these. Diffuse illumination has a number of advantages for examining the limbal conjunctiva.
- 2: B. The patient's limbal conjunctiva shows mild injection and should be recorded as grade 2.
- 3: D. These are all possible causes of limbal hyperaemia. Infection is unlikely since comfort remains good.
- 4: A. In view of her working hours and long history of soft lens wear, refit with SiH lenses and replace more frequently.

EDUCATIONAL MOMENTS[®]

Johnson & Johnson

VISION CARE INSTITUTE

How to manage patients with Limbal Redness (Limbal Hyperaemia)

FURTHER READING/REFERENCES

Keir N, Woods J and Sickenberger W. The conjunctival response to contact lens wear: a practical guide. *Optometry in Practice* 2010;11:3 123-134.

[CLICK HERE TO ACCESS](#)

Pult H, Murphy PJ, Purslow C *et al.* Limbal and bulbar hyperaemia in normal eyes. *Ophthalmic Physiol Opt* 2008;28:1 13-20.

[CLICK HERE TO ACCESS](#)

Riley C, Young G and Chalmers R. Prevalence of ocular surface symptoms, signs, and uncomfortable hours of wear in contact lens wearers: the effect of refitting with daily-wear silicone hydrogel lenses (senofilcon a). *Eye Contact Lens* 2006;32 281-6.

[CLICK HERE TO ACCESS](#)

Young G and Coleman S. Poorly fitting soft lenses affect ocular integrity. *CLAO J* 2001;27:2 68-74.

[CLICK HERE TO ACCESS](#)

Papas E. The role of hypoxia in the limbal vascular response to soft contact lens wear. *Eye Contact Lens* 2003;29:1 S72-4.

[CLICK HERE TO ACCESS](#)

Papas E, Vajdic C, Austen R *et al.* High oxygen-transmissibility soft contact lenses do not induce limbal hyperaemia. *Curr Eye Res* 1997;16:9 942-8.

[CLICK HERE TO ACCESS](#)

Papas E. On the relationship between soft contact lens oxygen transmissibility and induced limbal hyperaemia. *Exp Eye Res* 1998;67:2 125-131.

[CLICK HERE TO ACCESS](#)