

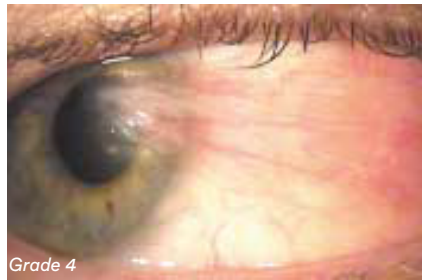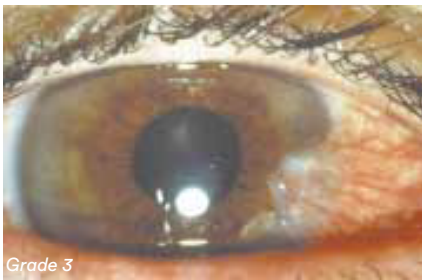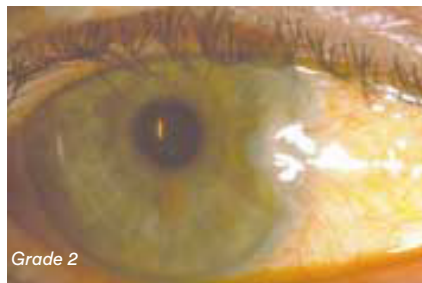
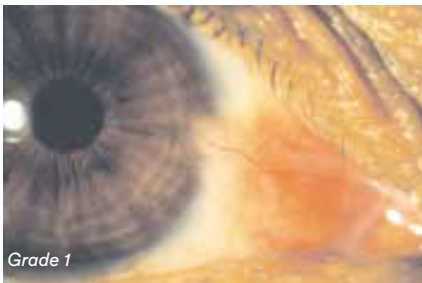# Educational Moments®

## How to manage patients with Pterygium

### WHAT YOU NEED TO KNOW

**Slit Lamp Viewing:** • Diffuse beam • Medium magnification (16x) • Direct illumination

#### Grading:



- Position: nasal/temporal
- Grade 0: None visible at limbus
- Grade 1: Touching limbus
- Grade 2: 1-2mm inside limbus
- Grade 3: 2-3mm inside limbus
- Grade 4: >3mm inside limbus

#### Incidence:

- Environment affects development - incidence varies depending on geographical location (levels of UV radiation exposure) and if closer to equator, more likely to develop pterygium
- Prevalence rates vary from < 2% in upper latitudes to 36% in lower latitudes.
- Heredity affects incidence (more common in persons of Spanish and Oriental origin)
- Not CL related but may impact CL comfort and wear time

#### Aetiology:

- Degenerative collagen bundles in bulbar conjunctiva due to excessive exposure of the bulbar conjunctiva to hot, dry, windy climates and/or UV radiation

#### Symptoms:

- Some discomfort with or without lens wear, dryness
- Cosmetic concerns
- Vision affected if becomes large due to corneal distortion inducing astigmatism

#### Signs:

- Triangular growth of fibrovascular tissue on bulbar conjunctiva, usually nasal, which encroaches onto cornea and destroys Bowman's membrane
- Often bilateral

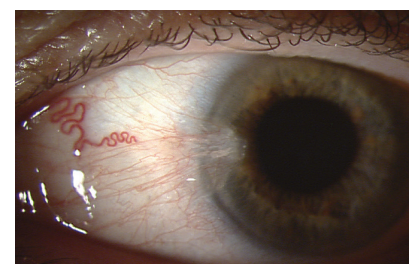


Figure 1: Medium magnification view of nasal pterygium

# Educational Moments<sup>®</sup>

## How to manage patients with Pterygium

### WHAT YOU NEED TO RECOMMEND TO YOUR PATIENTS

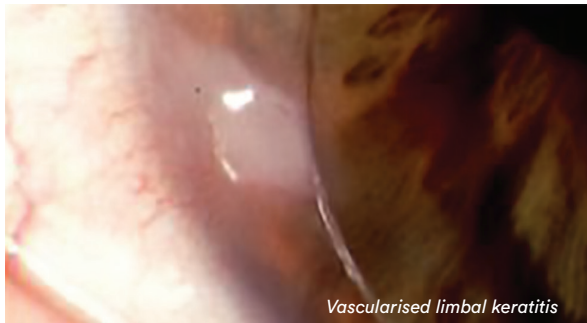#### Management:

- Only if discomfort occurs or if it interferes with vision — avoid mechanical trauma
- Not a contraindication for CL wear
- Occasional use of vaso-constrictors and ocular lubricants
- If severe, surgical removal may be required, followed by application of steroids, Mitomycin C or amniotic membrane
- Use of UV protection with wrap around sunglasses to prevent further deterioration

#### Prognosis:

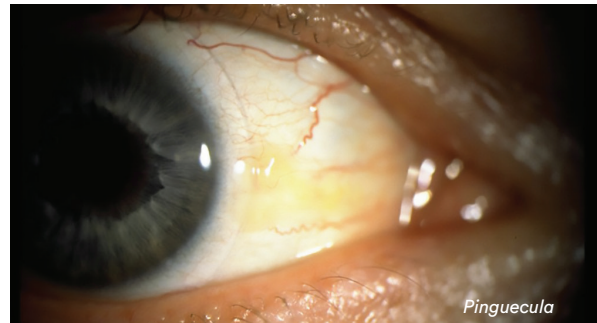
- Contact lens fitting possible as long as satisfactory physical fit can be obtained
- If surgical removal required, prognosis fair although re-growth occurs in 40% cases Note: condition associated with 2 to 3x increased risk of incident late and early Age Related Macular Degeneration (ARMD)

#### Differential Diagnosis:



Vascularised limbal keratitis

Vascularised limbal keratitis (VLK) — chronic inflammatory complication due to rigid lens design resulting in elevated, semi-opaque epithelial lesion at limbus with conjunctival hyperemia, corneal staining and neovascularisation.



Pinguecula

Pinguecula - a raised yellowish nodule on bulbar conjunctiva (nasally and/or temporally adjacent to limbus). See previous moment on [Pinguecula](#).

### FURTHER READING

- Janson BJ, Sikder S. Surgical management of pterygium. *Ocul Surf* 2014; 12: 112-9
- Jaros P, DeLuise V. Pingueculae and pterygia. *Surv Ophthalmol* 1988; 33: 41-49
- Linaburg T et al. Systematic Review: Effects of Pterygium and Pingueculum on the Ocular Surface and Efficacy of Surgical Excision. *Cornea* 2021; 40: 258-267
- Martins T et al. Mitomycin C in pterygium treatment. *Int J Ophthalmol* 2016; 9: 465-8
- Nouredin G, Yeung S: The use of dry amniotic membrane in pterygium surgery. *Clin Ophthalmol* 2016; 10: 705-12
- Pham T et al. Pterygium/pinguecula and the five-year incidence of age-related maculopathy. *Am J Ophthalmol* 2005; 139 (3): 536-5377
- Prediger J, Edmondson L. Management of CL patients with pingueculae or pterygia. *Optom Vis Sci* 1993; 70(1): 9-14
- Sheppard J et al.: An update on the surgical management of pterygium and the role of loteprednol etabonate ointment. *Clin Ophthalmol* 2014; 8: 1105-18

[Click here to review our Slit Lamp Techniques Videos](#)

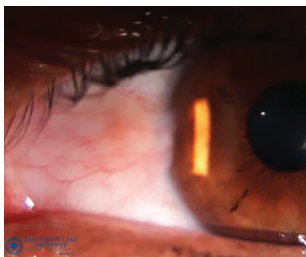
# Educational Moments®

## How to manage patients with Pterygium

### PATIENT CASE STUDY

When you have read this guide and our recommended resources, why not take part in the Johnson & Johnson Institute self-assessment quiz to test your clinical, diagnostic and management skills. Choose only one answer to each question then check the answers at the foot of the page to see whether it's correct. Good luck!

#### History:



*Patient SP is a 45-year-old engineer who has been working in the construction industry in the Middle East for the past five years. She wears monthly replacement silicone hydrogel lenses with no UV-blocker incorporated. Although she has noticed her eyes appear red she reports no discomfort with or without her lenses.*

#### Questions:

1. What slit lamp technique would you use to examine this patient's bulbar conjunctiva?

- |                       |                                      |
|-----------------------|--------------------------------------|
| A. Sclerotic scatter  | B. Diffuse beam, medium illumination |
| C. High magnification | D. Indirect illumination             |

2. What grade would you give to his Pterygium?

- |            |            |
|------------|------------|
| A. Grade 1 | B. Grade 2 |
| C. Grade 3 | D. Grade 4 |

3. Which of the following environmental conditions are associated with this condition?

- |                                |                     |
|--------------------------------|---------------------|
| A. Air-conditioned offices     | B. Shady conditions |
| C. High levels of UV-radiation | D. Humid conditions |

4. Which of the following contact lens options would you recommend for this patient?

- |   |                          |
|---|--------------------------|
| A. Switch to UV blocking contact lenses and wraparound sunglasses | B. Refit with RGP lenses |
| C. Cease contact lens wear permanently                            | D. Orthokeratology       |

#### Answers:

1. Correct answer is B.

Use a diffuse beam, medium magnification and direct illumination to examine the bulbar conjunctiva

2. Correct answer is A.

Grade 1 Slit-lamp examination of the bulbar conjunctiva shows the pterygium just touching the limbus

3. Correct answer is C.

High levels of UV radiation, along with living in equatorial regions, are associated with pterygium

4. Correct answer is A.

Assuming a satisfactory fit can be achieved. Wraparound sunglasses and UV-blocking contact lenses, plus a wide-brimmed hat, can help protect eyes from UV transmission\*

\*UV-absorbing contact lenses are not substitutes for protective UV-absorbing eyewear such as UV-absorbing goggles or sunglasses because they do not completely cover the eye and surrounding area.

**Important Safety Information:** ACUVUE® Contact Lenses are indicated for vision correction. As with any contact lenses, eye problems, including corneal ulcers, can develop. Some wearers may experience mild irritation, itching or discomfort. Contact lenses should not be used in case of eye infections or any other eye conditions, or in case of a systemic disease that may affect the eye. For detailed product information, including contraindications, precautions and adverse reactions, please consult the Instructions for Use or visit our Johnson & Johnson Vision website: <https://jnjvisionpro.co.uk/instructions-for-use>.